

# Genital herpes

M. Rogl Butina

---

## SUMMARY

Genital herpes is one of the most common sexually transmitted diseases in the world. It results from the infection with herpes simplex virus, commonly with herpes simplex virus type 2, occasionally with type 1. The infection is life-long, and after the initial episode, recurrences can appear any time. The virus is able to elicit a number of pathological conditions; however the recurrent clinical outbreaks of genital herpes most often cause not only physical but also psychosocial problems.

We present a brief overview of current concepts regarding the epidemiology, pathology, clinical manifestations and treatment options.

---

## Introduction

Herpes simplex virus (HSV) infection is today supposed to be the most common cause of genital ulcerations in industrialized countries. As such it causes physical and probably even more important psychosocial morbidity, besides it is coinvolved in a number of other pathological conditions.

It can result from the infection with HSV type 1 and HSV type 2, both usually result from contact with infected secretions on genital or oral mucosal surfaces.

The two viruses belong to the Herpesviridae family, more precisely to the group of alphaherpesviruses. Both are approximately 150–220 nm in diameter and have a similar structure: the inner core with a double stranded DNA genome in a protective capsid consisting of seven different proteins. Around the capsid is the tegument, which is in turn surrounded by the lipid membrane

where the herpesvirus glycoproteins are embedded. (Figure 1)

The genomes of HSV 1 and HSV 2 are dissimilar enough to be distinguished as two species (1). On the other side most of their antigens are very much alike, and among the glycoproteins on the surface only one (glycoprotein G) has been found to be sufficiently characteristic to be used as the antigen for the type specific serology. Glycoprotein G1 (HSV 1) consists of approximately 150 aminoacids, whereas G2 (HSV 2) has 600 aminoacids.

Humans are the only known hosts' reservoir for HSV. Infection and clinical manifestations of genital herpes can occur with both types, HSV 2 still being more frequently the cause. The reason for this is not yet clear, currently it is thought that it may be due to the diffe-

## KEY WORDS

herpes simplex virus, herpes simplex, genital ulcer, high risk sexual lifestyle

rences in the propensity of each virus to reactivate in either the trigeminal or sacral ganglia (2). However, in the recent CDC reports (3) HSV 1 is etiologically implicated in 5–30 % initial episodes of genital herpes, and among HSV 1 positive individuals 15 % are supposed to have genital involvement from this virus (4).

## Epidemiology

Serosurveys for type specific antibodies have shown a significant increase in prevalence of HSV 2 in the last decade (5,6,7). The last National health and nutrition examination survey in USA study (7) reports a 21,9 % seroprevalence in USA (white persons: 15 % men, 20 % women, and in black persons 35 % men, 55 % women were seropositive). Ashley and all. (8) report that HSV 2 seroprevalence reaches up to 50 % among women attending sexually transmitted diseases (STDs) clinics, and is between 60–90 % in female sex workers world wide. Most epidemiological studies of HSV 2 reported the highest incidence in the third decade of life, but recently a strong increase in seroconversion rates among teenagers was observed (7). Epidemiologically the presence of antibodies against HSV type 2 seems to be an important serological marker of sexual lifestyle (higher risk) in populations (9).

In Slovenia the seroprevalence study on HSV 1 and HSV 2 is still going on, but the preliminary results show much lower infection rates compared to the above mentioned reports.

## Pathology and clinical manifestations

Clinical manifestations of genital herpes are various and depend mostly on the type of the virus, previous exposure to herpes simplex virus, immunologic condition and gender of the patient.

Herpetic lesions can either be initial genital herpes or a recurrent one. The initial genital herpes can be a true primary genital herpes, that is the first episode of the disease without an evidence of prior herpes simplex infection (negative history and serology). It can also be a non-primary initial genital herpes where, during the time of the first clinically apparent episode, the serological signs of prior infection are present.

During the initial infection, the squamous epithelial cells of the epidermis are infected, they become swollen and lysed, multinucleated cells may also be observed. As a result vesicles form (ballooning), containing edematous cells and cell groups, and are accompanied by an inflammatory mononuclear infiltrate in the dermis.

In the vesicle fluid interferons and cytokines can be detected. After the vesicle ruptures HSV is shed for approximately 10 days from the remaining ulcer. (Figure 2). The ulcer becomes crusted; epithelization occurs in 21 days (2).

True primary genital herpes usually presents 2–14 days after the infection with HSV with patches of inflammation, reddened mucosa, vesicles and erosions spread over the major part of genitalia. Together with local disturbances (dysuria, urethral and vaginal discharge, regional lymphadenopathy) patients often develop systemic symptoms (fever, myalgia, fatigue, and photophobia). The disease has usually milder course in the individuals who had had prior HSV 1 infection and later develop genital HSV 1 or HSV 2 infection (10). In general the symptoms are more pronounced in women.

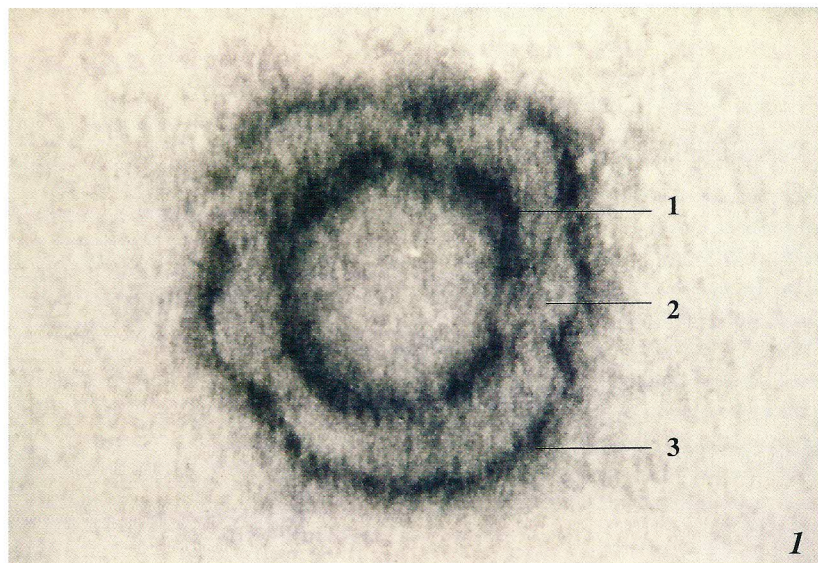
The differential diagnosis of initial genital herpes, especially when they are connected with systemic symptoms includes various causes of genital ulceration: syphilis, chancroid, erythema exsudativum multiforme, Behçet syndrome etc. Complications following the initial episode appear more often in women, the most frequent being extragenital cutaneous lesions, yeast superinfections, involvement of central and peripheral nervous system, erythema exsudativum multiforme.

Around 50 % of the patients presenting with initial episode of genital herpes are actually experiencing a non-primary outbreak. The already present immune response most probably attenuates the severity of those episodes, and lesions are less widespread, systemic symptoms and/or complications often missing.

After the infection of the skin the virus enters the cutaneous endings and ascends within the peripheral sensory nerves until it reaches spinal or trigeminal ganglia. In these neurons HSV either replicate furthers (productive infection) or enters a state of latency. During the latent state only a small part of the genome replicate (latency associated transcripts-LATs), though the part that codes the synthesis of viral proteins is never replicated. In the time of reactivation virus starts a complete replication again, it is actively transported to axons and then to nerve endings from where it attacks the epidermal cells again. As a rule processes of reactivation and transport cause no damage to the neurons.

Stimuli that most often induce the reactivation are ultraviolet light, trauma, and menstruation, physical and emotional stress or various acute and chronic disorders. Their systemic messengers include adrenaline and other stress hormones, whereas the local mediators are prostaglandins (PG), especially PG E<sub>2</sub> and PG F<sub>2</sub> (11).

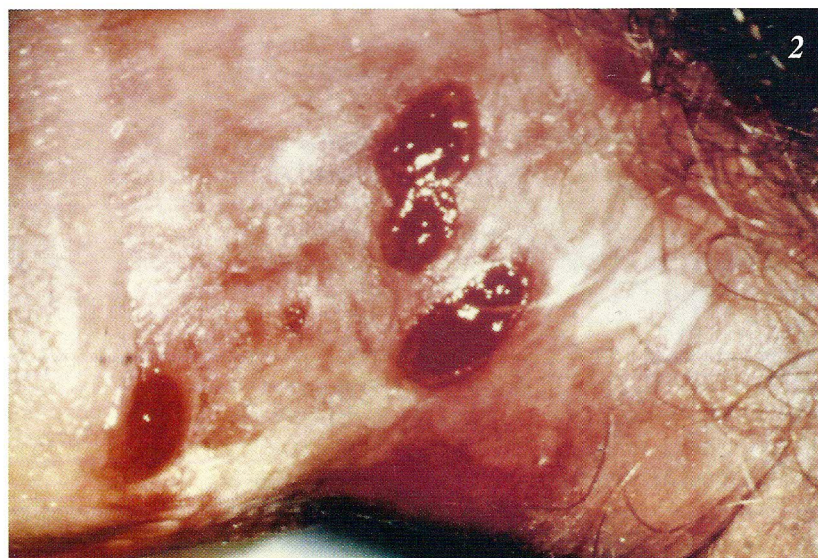Recurrent genital herpes refers to the second and all the following clinical episodes. It is quite often asymptomatic or non-recognised (6). It is hardly overlooked in its typical clinical presentation: ery-



thematous patches with grouped vesicles, their content is in the beginning clear, later it often becomes purulent; soon (after 1 – 2 days) the vesicles erode leaving small round ulcerations (for 2 – 3 days) which heal with a crust (in 5 – 6 days). In that form it is ordinarily more painful and lasts longer in women. Around 50 % of patients notice prodromal symptoms of burning/itching, paraesthesias, rarely also sacral neuralgia. (Figure 3).

It is however estimated that approximately one third of infected patients undergo asymptomatic infections and another third display atypical presentations: from non-painful ulceration to edema, small crusts, fissures, small erythematous patches or only a transient irritation.

With recurrent genital herpes complications are relatively rare, mostly they present as neuralgias, lymphangitis, erythema exsudativum multiforme and sometimes urethral strictures.



Recurrences of genital herpes are almost regular in the first two years after the initial outbreak. The estimated median rate of recurrences is 5 outbreaks per year, but actually there is marked variability among patients. They are more frequent with HSV 2 infection (80 – 90 % of individuals) than with HSV 1 infection (50 – 60 %) (12,13) and many more patients are experiencing asymptomatic or subclinical viral shedding.

### Transmission

Transmission of HSV may occur both during clinically evident outbreaks and asymptomatic virus shedding. Even though the risk is significantly higher with active herpetic lesions, asymptomatic viral shedding is probably the primary mode of transmission (13). It occurs by close personal contact (mostly sexual contact) and it appears to be most efficient from men to women. Studies of serologically discordant heterosexual couples report transmission rate between 10 – 12 % per year (14,15).

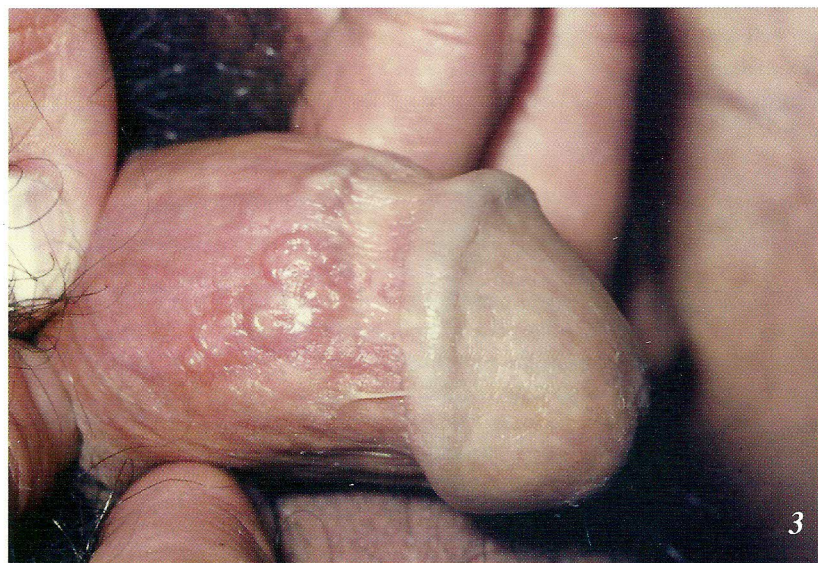

Figure 1. Electrone micrograph of Herpes simplex virus: (1) capsid, (2) tegument, (3) lipid membrane with glycoproteins

Figure 2. Initial (primary) genital herpes in a male

Figure 3. Recurrent genital herpes in a male

## Immunity

The role of immune response in genital herpes is not quite understood yet, but it seems that both parts (i) the non-specific response /natural killer cells, activated macrophages, production of interferon/ and (ii) the specific immune reactions /anti HSV IgM and IgG antibodies, CD<sub>4</sub> cells activity/ are important. Lately, also the knowledge of ways by which HSV evades the immune system defense is growing. The viruses down regulate MHC class I antigen expression on the surface of infected cells and consequently render CD<sub>8</sub> cells inactive against those cells. They can also inactivate complement and immunoglobulins by binding to them via certain HSV glycoproteins.

Any further impairment of immune system (immunosuppressive therapy in organ transplantation, HIV infection etc.) increases the probability of (i) clinically evident disease (ii) extensive local changes (iii) dissemination of lesions and (iv) further complications (1).

## Diagnostic procedures

There are many diagnostic procedures available, most of them being highly specific and sensitive if we respect their limitations. Various tests performed in the Institute of Microbiology and Immunology, Medical Faculty Ljubljana, are listed and specified in the paper of Marin et al. (16).

The interpretation of laboratory results frequently remains inconclusive and makes the decision concerning the treatment difficult. (17)

## Treatment

Elimination of herpesviruses from neuron is not possible yet; therefore the presently recommended treatment is aimed at controlling the disease with chemotherapy.

For the initial genital herpes episode systemic treatment with antiviral drugs is advisable. In Slovenia we can choose between acyclovir (Virolex<sup>®</sup> tbl. a 200 mg): 5 x 1 tbl./day, 7 -10 days, and valacyclovir (Valtrex<sup>®</sup> tbl. a 500mg) 2 x 1 tbl. /day, 7 - 10 days. Famcyclovir, which is not available in our country at the moment, is a prodrug of pencyclovir and the recommended schedule is 250 mg 3 times a day, 7-10 days. The above mentioned treatments are supposed to alleviate the systemic symptoms, shorten the duration of herpetic lesions and of viral shedding, but they do not effect the establishment of latency or the frequency of future recurrences.

For the recurrent episodes three possible regimens of therapy are recommended (at present):

a) Topical treatment: either with indifferent substances (for example with zinc oxide) or with topically applicable antivirals.

b) Episodic management with systemic antivirals: recommended drugs being again acyclovir 200 mg 5 times / day, valacyclovir 500 mg twice a day, famcyclovir 250 mg 3 times / day. All regimens should be performed for 5 days (18). Regarding the initiation of the treatment it has been shown that the most efficient regimen is the so-called patient initiated management, where the patient is trained to recognize prodromal symptoms and early signs and starts the therapy immediately. The episodic treatment reduces the time of herpetic lesions and subclinical viral shedding but does not affect the latency.

c) Continuous suppressive therapy: it is recommended for the patients who have very severe or/and frequent recurrences (more than six a year) or are immunologically incompetent and to those who are psychically and socially very disturbed by the disease.

In several studies it has been reported that suppressive treatment (acyclovir 400 mg / 12 h, valacyclovir 500 mg once a day, famcyclovir 250 mg /12h) significantly reduce not only clinical outbreaks but also asymptomatic viral shedding and as such it may importantly diminish the transmission (19,20,21).

At present the application of vaccines (therapeutic or preventive) is still in an experimental stage. Some of the vaccines in the past have been discarded because of the possibly carcinogenic effect and in the seventies Nasemann (22) even proposed that future herpes vaccines be manufactured only from primarily non-oncogenic strains. In Europe heat killed whole virus vaccines have been widely available in the last three decades, but only few controlled studies have been reported (23,24) From more recent reports the most promising seem to be the genetically engineered products and recombinant HSV glycoprotein vaccines (25,26).

## Conclusion

The HSV infections are relatively frequently observed in the STD clinics. The initial infection and especially the recurrences are annoying for the patient, but are not life endangering, except for the severely immunocompromised persons. Its direct role in carcinogenicity is being denied during the last decade, nonetheless it is one of the STDs, which as a bulk are an important cofactor in promotion of carcinoma of genitals.

## REFERENCES

1. Rouse BT, editor. Herpes simplex virus. Berlin Heidelberg New York: Springer Verlag; 1992.
2. Cunningham AL, Flexman JP, Dwyer D, Holland D, editors. Clinician's manual on genital herpes. London: Science press; 1997.
3. Centers for Disease Control and Prevention. 1998 Guidelines for treatment of sexually transmitted diseases. *MMWR* 1998; 47:18-65.
4. Schomogyi M, Wald A, Corey L. Herpes simplex virus-2 infection: An emerging disease? *Infect Dis North Am* 1998; 12: 47-61.
5. Nahmias AJ, Lee FK, Beckman-Nahmias S. Sero-epidemiological and sociological patterns of herpes simplex infection in the world. *Scand J Infect Dis* 1990; 69: 19-36.
6. Siegel D, Golden E, Washington E, Morse SA, Fullilove MT, Catania JA, Marin B, Hulley SB. Prevalence and correlates of Herpes simplex infections. The population-based AIDS in multiethnic neighborhoods study. *JAMA* 1992; 268: 1702-8.
7. Fleming DT, McQuillan GM, Johnson RE et al. Herpes simplex virus type 2 in the United States, 1976 to 1994. *N Engl J med* 1997; 337: 1105-11.
8. Ashley RL, Wald A. Genital herpes: review of the epidemic and potential use of type specific serology. *Clin Microbiol R* 1999; 12: 1-8.
9. Cowan FM, Johnson AM, Sahley R, Corey L, Mindel A. Antibody to herpes simplex virus type 2 as serological marker of sexual lifestyle in populations. *BMJ* 1994; 309: 1325-9.
10. Kinghorn Gr. Limiting the spread of genital herpes. *Scand J Infect Dis* 1996; 100: 20-5.
11. Pereira FA. Herpes simplex: evolving concepts. *J Am Acad Dermatol* 1996; 26: 698-709.
12. Benedetti J, Corey L, Ashley R. Recurrence rates in genital herpes after symptomatic first episode infection. *Ann Int Med* 1994; 121: 847-54.
13. Corey L. The current trend in genital herpes: progress in prevention. *Sex Transm Dis* 1994; 21: S38-S44.
14. Bryson Y, Dillon M, Bernstein DI, Radolf J, Zakowski P, Garratty E. Risk of acquisition of genital herpes simplex virus type 2 in sex partners of persons with genital herpes: a prospective couple study. *J Infect Dis* 1993; 167: 942-6.
15. Mertz GJ, Benedetti J, Ashley R, Selke SA, Corey L. Risk factors for the sexual transmission of genital herpes. *Ann Intern Med* 1992; 116: 197-202.
16. Marin J. Laboratorijska diagnostika herpetičnih obolenj. *ACTA dermatoven APA* 2000; in print.
17. Barton SE. The practical application of serological testing for HSV infection. *Herpes* 1998; 5: 39-41.
18. Reichman RC, Badger GJ, Mertz GJ. Treatment of recurrent genital herpes simplex infections with acyclovir: a controlled trial. *JAMA* 1984; 251: 2103-7.
19. Tyring SK, Douglas JM, Corey L, Spruance SL, Esmann J. A randomized, placebo-controlled comparison of oral valacyclovir and acyclovir in immunocompetent patients with recurrent genital herpes infections. *Arch Dermatol* 1998; 134: 185-91.
20. Goldberg LH, Kaufman R, Kurtz G et al. Long term suppression of recurrent herpes with acyclovir: a 5-year benchmark. *Acyclovir Study Group. Arch Dermatol* 1993; 129: 582-7.
21. Wald A, Zeh J, Barnum G, Davis LG, Corey L. Suppression of subclinical shedding of herpes simplex virus type 2 with acyclovir. *Ann Intern Med* 1996; 124: 8-15.
22. Nasemann T. Herpes simplex type 2 vaccine: the favorable european experience. *Int J Dermatol* 1976; 15: 587-8.
23. Calista D, Baldari U. Trattamento profilattico delle infezioni erpetiche recidivanti mediante immunostimolazione specifica con Lupidon G o H. *G Ital Dermatol Venereol* 1997; 132: 27-32.
24. Mastrolorenzo A, Tiradritti L, Salimbeni L, Zuccati G. multicentre clinical trial with herpes simplex virus vaccine in recurrent herpes infection. *International Journal of STD&AIDS* 1995; 8: 431-435.

25. Parr D, Savarese B, Burke RL, Margolis D, Meier J, Markoff L et al. Ability of recombinant herpes simplex virus type 2 glycoprotein D vaccine to induce antibody titers comparable to those following genital herpes. *Clin Res* 1990; 39:216A
26. Baltimore D. Intracellular immunization. *Nature* 1988; 395-6.

**A U T H O R ' S** *Mirjam Rogl Butina MD, dermatovenereologist, Dpt. Dermatovenereology,*  
**A D D R E S S** *Clinical Centre, Zaloška 2, 1525 Ljubljana, Slovenia*